

Report of a Severe Case of Pancytopenia Caused by Chronic Brucellosis in Tongliao City, Inner Mongolia Autonomous Region, China

Guoqing Zhang^{1,2}, Shuai Zhang¹, Leheng Zhao¹ and Jingbo Zhai^{1,3*}

¹Innovative Institute of Zoonoses, Inner Mongolia Minzu University, Tongliao, 028000, China

²Laboratory of Hulunbuir City People's Hospital, Hulunbuir City, 021008, China

³Key Laboratory of Zoonose Prevention and Control at Universities of Inner Mongolia Autonomous Region, Tongliao 028000, China

*Corresponding author:

Jingbo Zhai,

Innovative Institute of Zoonoses, Inner Mongolia Minzu University, Tongliao, 028000, China; Brucellosis Prevention and Treatment Engineering Research Center of Inner Mongolia Autonomous region, Tongliao 028000, China; Key Laboratory of Zoonose Prevention and Control at Universities of Inner Mongolia Autonomous Region, Tongliao 028000, China E-mail: jbzhai@imun.edu.cn

Received: 16 Oct 2022

Accepted: 25 Oct 2022

Published: 29 Oct 2022

J Short Name: ACMCR

Copyright:

©2022 Jingbo Zhai. This is an open access article distributed under the terms of the Creative Commons Attribution License, which permits unrestricted use, distribution, and build upon your work non-commercially

Citation:

Jingbo Zhai, Report of a Severe Case of Pancytopenia Caused by Chronic Brucellosis in Tongliao City, Inner Mongolia Autonomous Region, China. *Ann Clin Med Case Rep.* 2022; V10(3): 1-4

Keywords:

Brucellosis; pancytopenia; bone marrow suppression

#Contributed equally; Guoqing Zhang^{1,2#}, Shuai Zhang^{1#}

1. Abstract

Brucellosis is a type of zoonotic infectious disease that causes serious harm to public health. Inner Mongolia has become one of the most severely endemic areas of brucellosis in China. Human brucellosis is prone to involve multiple systems, which can cause a variety of complications. In this paper, we here reported a case of chronic brucellosis with pancytopenia, diagnosed and treated were retrospectively analyzed. hoping to promote awareness of brucellosis among clinicians and provide a basis for better clinical diagnosis and treatment.

2. Introduction

Brucellosis is a common zoonotic infectious disease with global distribution, accounting for at least 500,000 new cases annually [1]. It is widely prevalent in developing countries. According to the Statutory Infectious Diseases Report from China Centers for Disease Control (CDC), until May 23, 2021, a total of 26919 confirmed cases have been reported. Compared to the average for the same period from 2017 to 2019, the reported cases have risen by 70%. Especially in Inner Mongolia Autonomous Region shows the highest incidence rates for human brucellosis (HB), which reaches 34.5 cases per 100,000 in the first half of 2021 [2].

Due to the nonspecific and diverse clinical manifestations, HB is

prone to misdiagnosis. Patients with Brucella infections commonly present with headache, fever, fatigue, night sweats, joint pain, and muscle aches. The bacteria can invade multiple systems, resulting in varying degrees of damage and dysfunction. For the impact of Brucella on the blood system, chronic brucellosis patients often have anemia, leukocyte reduction, leukopenia, or deficiency. Also, thrombocytopenia leads to the occurrence of purpura, or bleeding. The present study reports the case of a patient diagnosed with chronic HB associated with pancytopenia, The detailed are as follow.

3. Case Report

A 57-year-old female patient, who is employed primarily in livestock farming. In June 2020, the patient diagnosed with this disease. The clinical manifestations disappeared through the antibiotic treatment, and the whole blood cell generally turned to normal levels. Figure 1 portrayed the patient diagnosis, treatment, and outcome. On April 20, 2022, the patient again visited the hospital complaining of fever and fatigue. The patient underwent clinical detection. The results were: Brucella serology SAT: 1: 200++++, WBC : $1.28 \times 10^9/L$, RBC: $3.63 \times 10^{12}/L$ PLT: $115 \times 10^9/L$ (Table 1). Then she was diagnosed with Brucellosis, along with pancytopenia. Treatment with rifampin and doxycycline was administered. During the treatment, the whole blood cell count

of the patient kept decreasing. Thus, the patient went to a larger hospital outside the province for further diagnosis and treatment. After bone marrow examination, the patient was diagnosed with bone marrow hyperplasia and bone marrow suppression caused by sepsis.

On May 5, 2022, the patient returned to Tongliao city, Inner Mongolia, and were admitted to the intensive care unit of the Affiliated Hospital of Inner Mongolia University for Nationalities. The examination was conducted and the results showed: fever: 39°C, acute fever, face fatigue, drowsiness, no lymph nodes, liver spleen abnormalities. The patient lost about 20 kg, and had a 20-year history of lumbar disc disease. On imaging examination, the results showed: mild inflammation of the right lung, multiple small nodules, and no obvious abnormalities. Laboratory examination: Experimental results ruled out the possibility of common viral infections, autoimmune diseases, and malignant tumor. Brucella serum

antibody (SAT: 1:200 ++), bone marrow culture is sheep type 3 Brucella and, multiple blood culture tests were negative. On May 10, whole blood was collected at Inner Mongolia University for Nationalities for a nucleic acid test and the results were positive. On May 24, whole blood was collected again for nucleic acid test and result were negative. The direct Coombs experiment showed a weak positive test.

According to the guide for treatment, The rifampicin and doxycycline antibiotics were administrated as well as the use of dexamethasone anti-inflammation, immunoglobulin infusion, recombinant human granulocyte stimulating factor, infusion of suspended red blood cells, and other symptomatic treatments were applied correspondingly. With this combined therapy for a week the patient felt much better with an improvement in whole blood index (Table 1). On June 5, the patient was transferred to the intensive care unit.

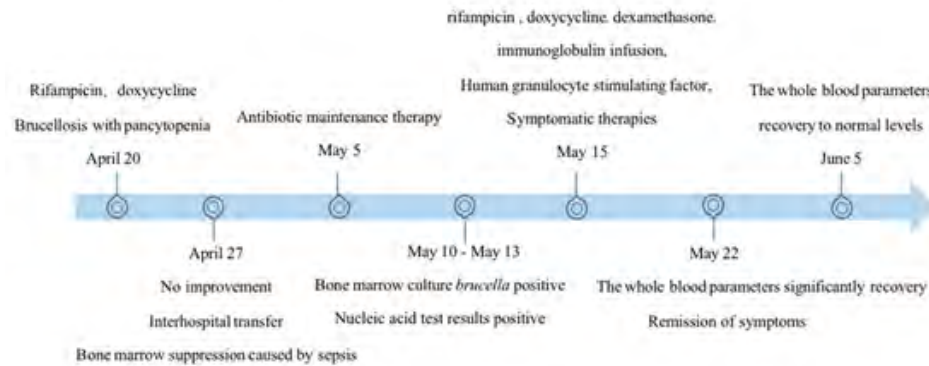


Figure 1: Timeline of key dates about patient condition the timeline (from April 20 to June 5) portrayed the patient's almost two-month diagnosis and treatment process.

Table 1: Blood routine clinical indicators results

Clinical indicators	Date						Reference range	Unit
	4.2	4.28	5.6	5.15	5.22	6.5		
White blood cell	1.28	0.25	0.23	0.57	4.61	10.24	3.50-9.50	10 ⁹ /L
Neutrophil	0.04	0.02	0.04	0.25	3.52	8.42	1.80-6.30	10 ⁹ /L
Neutrophil rate	2.3	5.9	17.4	43.9	76.4	82.3	40.0-75.0	%
Lymphocyte	0.85	0.24	0.18	0.28	0.84	1.09	1.10-3.20	10 ⁹ /L
Lymphocyte rate	95.5	90.1	78.3	49.1	18.2	10.6	20.0-50.0	%
Monocyte	0.01	0.01	0.01	0.04	0.24	0.7	0.10-0.60	10 ⁹ /L
Monocyte rate	1.1	4.3	4.3	7	5.2	6.8	3.0-10.0	%
Red blood cell	3.63	2.34	1.89	1.65	2.13	2.41	4.30-5.80	10 ¹² /L
Hemoglobin	117	79	59	53	65	75	130-175	g/L
Platelet	115	60	72	73	114	229	125-350	10 ⁹ /L
Hypersensitive C-reactive protein	110	84.68	113.4	235.83	130.42	110.21	0-10.0	mg/L
Alanine aminotransferase	7.3	7.5	7.4	6.9	14.9	15.6	9.0-50.0	U/L
Aspartic aminotransferase	15.6	15.9	17.1	7.1	19.3	50.21	10.0-60.0	U/L
Total bilirubin	15.6	17.7	33.7	89.1	49.9	43.1	3.40-17.10	umol/l
Direct bilirubin	11.2	13.4	28.8	75.6	32.8	30.4	0-3.40	umol/l
Indirect bilirubin	4.6	4.7	4.9	13.5	17.1	12.7	0-13.70	umol/l

4. Discussion

Brucella is a facultative intracellular parasite and gram-negative Coc bacterium that uses different strategies and expresses different virulence factors to evade the host immune response [3]. Brucella can persist in human macrophages, and it is difficult for the human immune system to remove this form of intracellular parasite. Many untreated antibiotic treatments or antibiotics have poor efficacy and can cause brucellosis chronicity or relapse. When immunity drops, Brucella parasites in macrophages multiply and cleave them to infect more phagocytes. When phagocytes spread throughout the body through lymphatic and blood circulation, they multiply and lyse, which can cause a strong immune response in the body.

In addition to the common clinical manifestations such as fever, fatigue, hyperhidrosis, and back pain, the most prominent features were pancytopenia and significant weight loss. Furthermore, the bone marrow puncture report suggested that the myeloid hyperplasia was extremely reduced and the bone marrow hematopoiesis was suppressed. The mechanism of bone marrow suppression is unknown, which may be caused by the release of Brucella itself or the produced metabolites, endotoxins, or because the immune inflammatory response of the body suppresses bone marrow hematopoiesis. Myelosuppression is an important cause of pancytopenia. In addition to myelosuppression, the severe pancytopenia in the short term should also be closely associated with the consumption of blood cells.

Neutrophils, the largest proportion of white blood cells in the blood, play the role of the first line of defense against microbial invasion and are an important part of human innate immunity. After the emergence of bacteria in the body, it will quickly phagocytose and kill the pathogen, while releasing cytokines to activate innate immunity. Because Brucella is a hidden pathogen, its special structure can resist the killing mechanism of these neutrophils. Infected neutrophils cannot release cytokines to activate innate immune [4], and Brucella LPS core part of lipid A can induce the premature death of neutrophils [5]. In this patient, the cells died prematurely after neutrophils phagocytose Brucella, and the neutrophils were low before the onset, so the white blood cells in the patient will be reduced. With too few leukocytes, a large number of Brucella released are phagocytosed by monocytes, macrophages, dendritic cells, producing cytokines, and antigen presentation leading to the rapid activation of adaptive immunity. This patient had been previously infected with Brucella, and large numbers of Brucella bacteria entering the blood could also rapidly activate memory T lymphocytes to release inflammatory factors. Extensive release of pro-inflammatory factors IL-2, IL-6, TNF- α , IFN- γ , and IL-12 activates monocyte macrophages to kill intracellular Brucella, activate pro-inflammatory TH1 cell immunity, and rapidly remove Brucella in patients. At the same time, the body will also release a large number of inflammatory factors, resulting in the formation of inflammatory factors storm. In some animal trials, Brucella in-

fection of mice lacking white blood cells also showed excessive inflammatory symptoms [6], this patient developed cachexia state due to excessive inflammatory conditions, manifested by rapid loss [7]. This shows that although neutrophils do not play an active killing role in the elimination of Brucella, they play an important role in buffering the destruction of immune inflammation in the body. Therefore, the number of white blood cells before the onset can theoretically serve as an important monitoring indicator for the weight of clinical symptoms.

Red blood cells are the most numerous cells in the human blood, which carry O₂, CO₂. And other important physiological functions, but also play an important role in immune function. In patients with brucellosis, inflammatory phenomena are often accompanied by the occurrence of anemia, and cytokines such as TNF- α , IL-1, IL-6, and INF- γ produced by pro-inflammatory cells also directly or indirectly limit erythrocyte generation and shorten the life span of erythrocytes [8]. The imaging and laboratory examination of the patient found no damaged hepatocytes and elevated transaminase. As the result of increased bilirubin levels, the destruction of red blood cells in the patient was increased. After the massive release of Brucella, which can enter the erythrocyte and hide [9-10]. In addition, some antigen components of Brucella or bacteria can adhere to the red blood cells, or the red blood cells that adhere to pathogens can be engulfed by macrophages, forming haemophagocytosis [11]. In many types of inflammatory diseases (e. g. bacterial sepsis, influenza, malaria, leishmaniasis, and active rheumatic disease), hemophagocytic syndrome has been described as the cause of the associated hemocytopenia [12]. The presence of incomplete red cell antibodies in the patient, which could also lead to increased blood cell destruction in the patient was shown through the positive direct Coombs test during the patient's hospitalization.

Platelets are an important part of the blood system and they play an important role in hemostasis and maintaining the integrity of blood vessels. The same platelets play an anti-infective role in Brucella-induced inflammation. It has been shown that platelets can directly interact with Brucella or invade inside the platelets, and can serve as Brucella carriers to promote the phagocytosis of monocytes / macrophages. The interaction of platelets with Brucella can activate platelets to establish complexes with monocytes. This interaction of platelet monocytes can trigger an increased in the proinflammatory response to infected monocytes [13]. Due to platelet activation, and promoting phagocytosis of monocyte macrophages, these can greatly consume platelets and reduce platelet numbers.

The results of our active treatment showed that a large number of Brucella bacteria were killed and cleaned up by the body's immune system and the antibiotics administrated. The myelosuppression has been relieved. However, there must be a small number of Brucella undergoing immune response, immune killing, immune escape, immune tolerance, and finally, due to the escape

mechanism hidden, *Brucella* can form a relatively calm and normal state between the pathogen and the host. The patient was diagnosed with brucellosis in 2020, and although there were no clinical symptoms. The leukocyte level has been low and may have been in chronic infection. The TH1 pro-inflammatory response that was determined by cytokine test results was not strong enough to clear *Brucella*. NK cells are the important immune cells of the body, and they play an important role in the clearance of *Brucella* infection [14-16]. It is also known from the relative count results of NK cell lymphocyte subsets that although the function of NK cells cannot be known due to the lack of corresponding detection, the number of NK cells tested has been far below the normal range. This also suggests that immune depletion is already present or already quite severe [17]. *Brucella* is endocytosed by monocyte macrophages through neutrophils, red blood cells, platelets, and is re-hidden in monocyte macrophages by Trojan horse. So the patient still has a long way to go before a complete recovery. Patients should take antibiotics on a regular basis, completely, and in conjunction with regular examination and guidance. At the same time, patients should strengthen their own nutrition, get adequate rest and engage in appropriate exercise to strengthen the recovery of their own immune function.

5. Conclusion

Chronic human brucellosis associated with pancytopenia is potential, severe complication. Diagnostic and treatment of human brucellosis remain challenging despite medical advances. Clinicians should be aware of the precise identification for the brucellosis results in proper therapy and a favorable outcome.

6. Funding

This work was supported by the grant from the National Natural Science Foundation of China (NO. 82160312); Key Laboratory of Mongolian Medicine Research and Development engineering, Ministry of Education open issue (MDK2021040); Brucellosis Prevention and Treatment Engineering Technology Research Center of Mongolia Autonomous region open issue (MDK2021077); Major science and technology projects of Inner Mongolia of China (2019ZD006).

7. Ethics approval and consent to participate

In this report, the requirement for ethics approval was waived by the Research Ethics Committee of Inner Mongolia Minzu University. (No. NM-LL-2022-05-31-01)

References

- Pappas G, Papadimitriou P, Akritidis N, Christou L, Tsianos EV. The new global map of human brucellosis. *Lancet Infect Dis*. 2006; 6(2): 91-99.
- Geng M, Ren X, Peng Z, Chang Z, Chen Q, Li Y, et al. Incidence of key infectious diseases in summer of 2021, China. *Disease Surveillance*. 2021; 36(8): 811-817.
- Celli J. The Intracellular Life Cycle of *Brucella* spp. *Microbiol Spectr*. 2019; 7(2): 10.
- Barquero-Calvo E, Chaves-Olarte E, Weiss DS, Guzmán-Verri C, Chacón-Díaz C, Rucavado A, et al. *Brucella abortus* uses a stealthy strategy to avoid activation of the innate immune system during the onset of infection. *PLoS One*. 2007; 2(7): e631.
- Barquero-Calvo E, Mora-Cartín R, Arce-Gorvel V, de Diego JL, Chacón-Díaz C, Chaves-Olarte E, et al. *Brucella abortus* Induces the Premature Death of Human Neutrophils through the Action of Its Lipopolysaccharide. *PLoS Pathog*. 2015; 11(5): e1004853.
- Moreno E, Barquero-Calvo E. The Role of Neutrophils in Brucellosis. *Microbiol Mol Biol Rev*. 2020; 84(4): e00048-20.
- Onesti JK, Guttridge DC. Inflammation based regulation of cancer cachexia. *Biomed Res Int*. 2014; 2014: 168407.
- Ganz T. Anemia of Inflammation. *N Engl J Med*. 2019; 381(12): 1148-1157.
- Vitry MA, Hanot Mambres D, Deghelt M, Hack K, Machelart A, Lhomme F, et al. *Brucella melitensis* invades murine erythrocytes during infection. *Infect Immun*. 2014; 82(9): 3927-3938.
- de Souza TD, de Carvalho TF, Mol JPDS, Lopes JVM, Silva MF, da Paixão TA, et al. Tissue distribution and cell tropism of *Brucella canis* in naturally infected canine fetuses and neonates. *Sci Rep*. 2018; 8(1): 7203.
- Bialer MG, Sycz G, Muñoz González F, Ferrero MC, Baldi PC, Zorreguieta A. Adhesins of *Brucella*: Their Roles in the Interaction with the Host. *Pathogens*. 2020; 9(11): 942.
- Gardenghi S, Renaud TM, Meloni A, Casu C, Crielaard BJ, Bystrom LM, et al. Distinct roles for hepcidin and interleukin-6 in the recovery from anemia in mice injected with heat-killed *Brucella abortus*. *Blood*. 2014; 123(8): 1137-1145.
- Trotta A, Velásquez LN, Milillo MA, Delpino MV, Rodríguez AM, Landoni VI, et al. Platelets Promote *Brucella abortus* Monocyte Invasion by Establishing Complexes With Monocytes. *Front Immunol*. 2018; 9: 1000.
- Bhagyaraj E, Wang H, Yang X, Hoffman C, Akgul A, Goodwin ZI, et al. Mucosal Vaccination Primes NK Cell-Dependent Development of CD8+T Cells Against Pulmonary *Brucella* Infection. *Front Immunol*. 2021; 12: 697953.
- Dornand J, Lafont V, Oliaro J, Terraza A, Castaneda-Roldan E, Li-autard JP. Impairment of intramacrophagic *Brucella suis* multiplication by human natural killer cells through a contact-dependent mechanism. *Infect Immun*. 2004; 72(4): 2303-2311.
- Golding B, Scott DE, Scharf O, Huang LY, Zaitseva M, Lapham C, et al. Immunity and protection against *Brucella abortus*. *Microbes Infect*. 2001; 3(1): 43-48.
- Bi J, Tian Z. NK Cell Exhaustion. *Front Immunol*. 2017; 8: 760.