

A Wandering Atrial Pacemaker in Inferior Wall Infarction. Escape or Survival Rhythm? A Case Reports

Naija M*, Mbarek R, Boukadida A and Chebili N

Department of Emergency Medical Service (SAMU 03) CHU Sahloul Sousse, Tunisia

*Corresponding author:

Mounir Naija,
Department of Emergency Medical Service (SAMU 03)
CHU Sahloul Sousse, Tunisia,
E-mail: mounirnaija@yahoo.fr

Received: 16 Jan 2021

Accepted: 03 Feb 2021

Published: 06 Feb 2021

Copyright:

©2021 Naija M et al., This is an open access article distributed under the terms of the Creative Commons Attribution License, which permits unrestricted use, distribution, and build upon your work non-commercially.

Citation:

Naija M. A Wandering Atrial Pacemaker in Inferior Wall Infarction. Escape or Survival Rhythm? A Case Reports. Ann Clin Med Case Rep. 2021; V5(11): 1-3.

1. Abstract

Coronary sinus rhythm is an ectopic atrial rhythm supposedly originating from a pacemaker at the mouth of the coronary sinus; recognized in the electrocardiogram by P-waves that are inverted in leads II, III, and VF with a normal or prolonged P-R interval. In myocardial infarction, this presentation can reveal a wandering atrial pacemaker. We present a case of a wandering atrial pacemaker with inferior wall MI complicated by complete atrioventricular block.

2. Introduction

Coronary sinus rhythm is an ectopic atrial rhythm supposedly originating from a pacemaker at the mouth of the coronary sinus; recognized in the electrocardiogram by P-waves that are inverted in leads II, III, and VF with a normal or prolonged P-R interval. In myocardial infarction this presentation can reveal a wandering atrial pacemaker.

We present a case of wandering atrial pacemaker with inferior wall MI complicated by complete atrio-ventricular block.

3. Case report

A 86-year-old woman was admitted to emergency department of a comminatory hospital due to persisting angina for an hour and syncope. Pain was 4/10 on scale His She had no previous medical history, a non-smoker. Electrocardiogram (ECG) showed ST segment elevation in leads II, III and VF and reciprocal ST segment depression in leads V1–V6. She was treated before the arrival of our prehospital team with dual oral antiplatelets such us aspirin

250 mg and clopidogrel 300 mg, intra venous loading doses of unfractionated heparin 50 mg and atropine (0,5 mg) for brady arrhythmia.

On physical examination by our prehospital physician the cardiac sounds and breathing were normal on auscultation. The patient was dizzy and somnolent. Her pulse was irregular at 50 bpm, her blood pressure was 50/30 mm Hg. The ECG showed ST elevation in leads II, III, Vf, V3, V4, V3R and V4R. an inverted P wave was noted in inferior leads consistent with coronary sinus rhythm complicated by a complete atrio-ventricular dissociation (Figure 1). She was medicated by Dobutamine at 10 γ /Kg/min with Nor-epinephrine at 0,5 mg/h. the patient was transferred to Cath lab for primary Percutaneous Coronary Intervention (PCI).

On the way, the ECG has changed and demonstrate Second Degree Heart Block (Mobitz type 2), ST segment elevation in leads II, III, Vf, V1, V3, V4 and V6 with low atrial rhythm (Figure 2).

On admission she was conscious, heart rhythm was irregular at 65 bpm, and blood pressure 80/50 mmhg. Serum troponin 0.30 ng/mL (normal range (NR) 0–0.14 ng/mL). His electrocardiogram showed sinus tachycardia with decrease in ST segment elevation (Figure 3).

After an initial evaluation, coronary angiography (CAG) was immediately performed and revealed total occlusion with a thrombus in the proximal segment of the right coronary artery (RCA) with a TIMI 0 flow. A Laying bare stent of (3 * 15mm) was placed with good result. During the course several ventricular Fibrillation occurred treated by electrical shock.

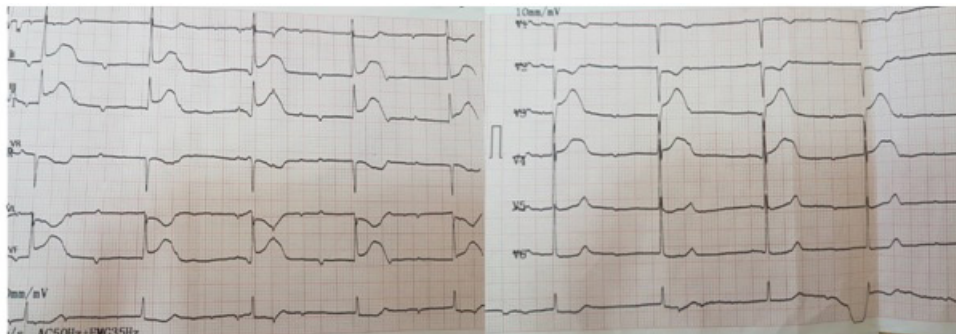


Figure 1: ECG showed ST elevation in leads II, III, V4, V3, V6 and an inverted P wave in inferior leads consistent with coronary sinus rhythm complicated by a complete atrio-ventricular dissociation and complete atrioventricular block.

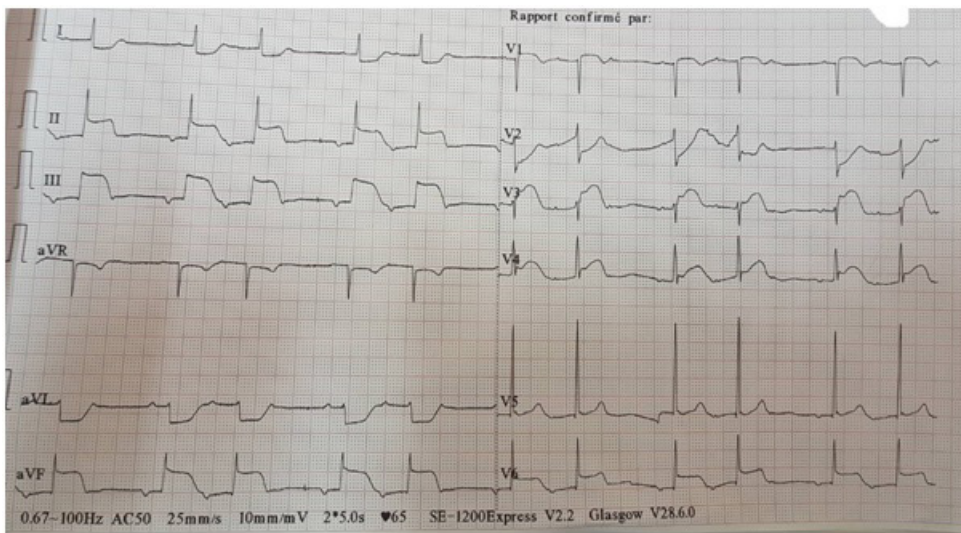


Figure 2: ECG showed Second Degree Heart Block (Mobitz type 2), ST segment elevation in leads II, III, V4, V1, V3, V4 and V6 with reciprocal ST depression in I, VL and V2. P wave inverted in inferior leads corresponding to low atrial rhythm.

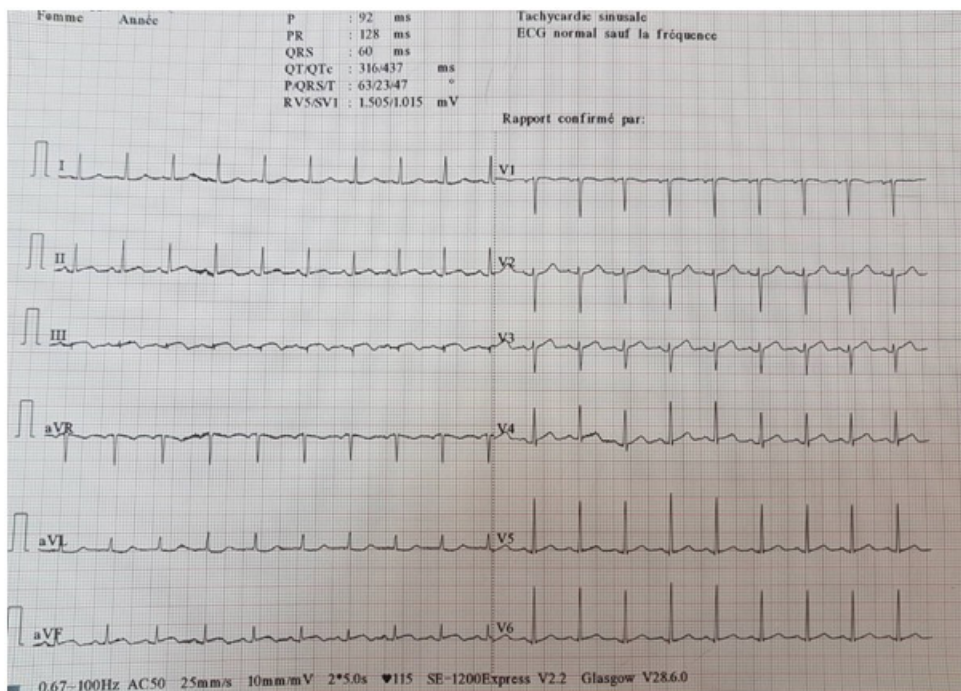


Figure 3: At admission ECG showed sinus tachycardia

After coronary angioplasty the ECG showed new-onset atrial fibrillation (AF) (Figure 4). The transthoracic echocardiography performed two days later revealed hypokinesia of the inferior wall with a good left ventricular ejection.

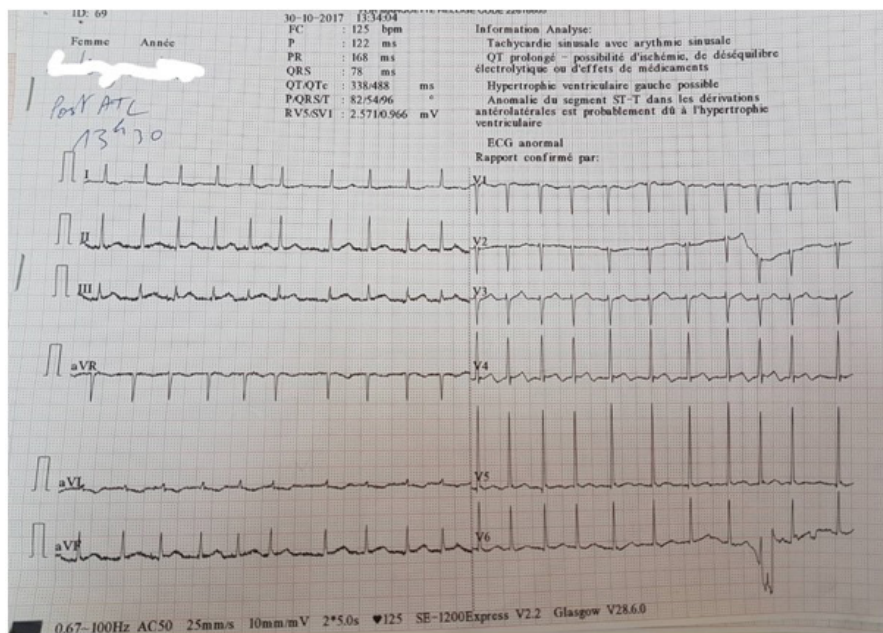


Figure 4: ECG post PPCI showed new-onset atrial fibrillation (AF) and minor ST segment elevation in inferior leads.

4. Discussion

A wandering pacemaker is a sign of cardiac irritability in the atrial. This dysrhythmia may occur in normal hearts as a result of fluctuations in vagal tone. Schamroth and Goldberg [2] attempted to clarify the definition of wandering pacemaker in 1972. They explained the mechanism of the wandering pacemaker as an escape rhythm overloaded with extreme bradycardia. They postulated that the sinus bradycardia was considered to be the main cause of the escape beat which occur in the first place, and it is a benign physiological condition. New theory concerning the wandering pacemaker have been described following the more in-depth studies of the anatomy and physiology of the sinoatrial node [2]. A recent review of physiology suggests too theories for P-wave changes morphology in the wandering stimulator. The variation of the initial stimulation signal in the sinoatrial node causes the change of the morphology of the p wave. The theory holds that too or more physiological pacing sites (leading and subsidiary) within the structure alternate the role of primary pacer during episodes of WAP. Following the change of the site of first stimulator, the wave of the action potential changes and consequently the axis of the P wave.

The other modern theory that could account for P-wave morphology changes is that the action potential comes from a very extended area: The sinoatrial node is actually a more extensive tadpole-shaped structure that includes a para nodal area and articulations into the atrial muscle structure. The potential action can come from a different location but the pacemaker site is stable, which explains the change of the P-wave axis in a single lead.

It has also been shown that a wandering atrial pacemaker is a potential long-term complication of high-dose sympathomimetics at toddler, [5].

In other study, the others described the possibility of atrial infarction

when considering inferior, and/or posterior infarctions with atrial arrhythmias, hypotension and a cardiac output status. Atrial infarction is frequently accompanied by a variety of complications include arrhythmia, rupture, loss of atrial 'kick' and thromboembolic phenomena. Wandering atrial pacemaker is not quite common in the setting of atrial infarctions [1]. In our case the WAP was associated with MI and cardiac outputs status. It's unfortunately possible to miss an association with atrial infarction which has been a relatively understudied entity.

5. Conclusion

This case is presented to highlight the possibility of WAP and hypotension and a cardiac output status with inferior myocardial infarction. PAW occurs on the occasion of a change of balance between sympathetic and parasympathetic tone this during this consequent rhythm as Benin can indicate a different speech. This may be a most enriching contribution when future studies are needed to determine if WAP in MI was B flat or a benign heart rate note.

Reference

1. Shakir DK, Arafa SOE. Right atrial infarction, atrial arrhythmia and inferior myocardial infarction form a missed triad: A case report and review of the literature. *Can J Cardiol.* 2007; 23(12): 995-997.
2. Schamroth L, Goldberg M. The concept of a wandering pacemaker. *Heart Lung.* 1972; 1 (4): 519-522.
3. Monfredi O, Dobrzynski H, Mondal T, Boyett MR, Morris GM. The anatomy and physiology of the sinoatrial node a contemporary review. *Pacing Clin Electrophysiol.* 2010; 33(11): 1392-1406.
4. Hannibal RN. Wandering Atrial Pacemaker and Multifocal Ectopic Atrial Tachycardia *Advanced Critical Care.* 2015; 26 (1): 73-76
5. Aburawi EH, Narchi H, Souid AK. Persistent wandering atrial pacemaker after epinephrine overdosing – a case report. *BMC Pediatr.* 2013; 13: 1.